Clinical occlusal caries detection methods to use in the general practice

Layla Nabaa l.nabaa@Queens-Belfast.AC.UK

Hisham Al Shorman

Professor Junji Tagami tagami.ope@tmd.ac.jp

E Lynch

Along with the evolution of dental materials and techniques for the management of dental caries, practices where these treatments are provided have changed. No longer does the detection of the caries process ultimately aim to amputate it by having the tooth drilled or extracted. Other minimal invasive treatment options are available along with an armament of non operative and preventive measures. This had led the clinical settings to take on different instruments to provide the least invasive options for the affected teeth and preventive procedures to the largest number of clinically unaffected teeth in "at risk" Patients. For a successful caries managing practice, the dental clinician and team are left to provide their patients with the correct diagnosis and risk assessments to form the strong basis on which all the rest is built and then offer monitoring means to follow-up on their treatment outcomes.

As a dynamic process under the influence of the ever-present, dental plaque activity, the carious process was described as the "unpreventable ubiquitous process" (Ekstrand et al, 2001). Occlusal surfaces account for only 12.5% of those surfaces exposed to the cariogenic challenges but 80%-90% of the total caries experienced in children and adolescents occur on them (Ripa et al, 1988, Anderson, 2002). High incidence rates for these carious lesions occur in a wide age range and take a long time before frankly cavitating (Ripa et al, 1988; Vehkalahti et al, 1991, ten Cate, 2001). This means that dentists will encounter these lesions at different stages in their regular general practice in most of their patients. Understanding these facts would allow the clinician to avoid supervised neglect and treat lesions more conservatively.

Once a sign is picked up for such carious activity, different tools are used to specifically diagnose different stages of lesions. These should be applied under optimal clinical conditions. An indispensable fine skill is further needed to refine the positive outcomes from other normal variations or pathological alterations of measurements detected by these tools.

What are these positive signs, which should ring the bell?

Diagnosis of caries comes as one heading on a long list of tasks required from the practitioner performing the dental examination on a new patient. This heading can be less attractive to the same practitioner examining a regular patient on their 6-monthly or yearly recalls. It heads down the list when the examination is focussed on a problem-oriented treatment other than caries treatment.

Nevertheless, there would be signs that could not be missed by a glance from an expert clinician's eye, as it should be. One condition remains essential in any examination, perform all dental examinations on clean teeth. This would become the norm if the practitioner understands that non-cavitated lesions are more prevalent than cavitated ones especially in low caries risk patients (Ismail et al, 1992) as well as understanding that the rates at which dentinal lesions develop are faster in the occlusal caries than in the smooth surface caries. Lesions in dentine were seen in teeth just over one year after eruption (Ekstrand and Bjorndal, 1997a) whilst the smooth surface lesions were noticed after a range of two to four years post eruption (Pitts, 1983).

1. Cavitated occlusal surface: This might be the easiest sign to detect but at the same time it is less prevalant than non-cavitated lesions (Ismail 1992).

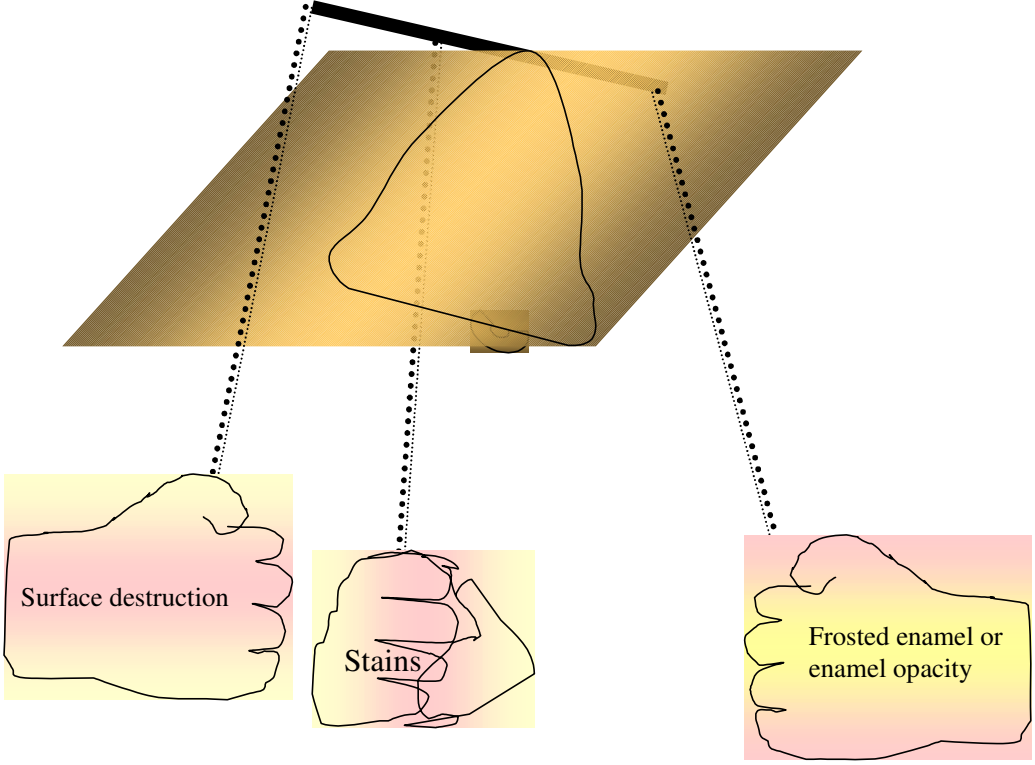

2. Frosted or opacity of enamel.
3. Discolouration of the surface. Can be brownish or black.

What should the dentist do once the bell is rung?

Once detected, the clinician must enter into an automatic mode of thinking, following a sequence of caries management protocols. These include providing further optimal clinical conditions aiding more signs to be detected, take out and use the correct tools, refine the positive tool outcomes due to caries from other variables producing the same results, reach a diagnosis specific to the lesion in terms of severity (depth, width, length, and mineral density), activity and attributing local risk factors, looking for other lesions in surfaces susceptible to the same local risk factors, make good records, then point out patient-specific risk for unaffected surfaces, advising the patient to alter these factors, provide interventions to the active caries process, and finally monitor lesions and compare with records.

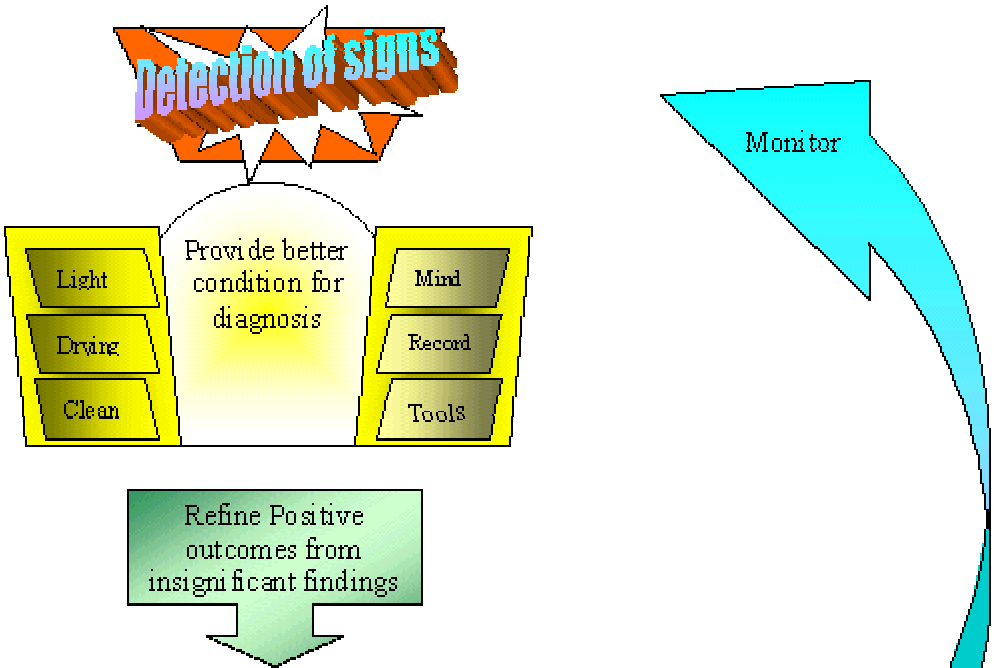

What are the optimal clinical conditions for caries diagnosis?

1. Caries-risk oriented thinking: The practitioner should focus on the diagnosis of the lesion taking into account all the local risk factors that could be associated with stagnant plaque accumulation. A positive correlation was found between plaque and enamel demineralisation whilst none was found between the clinical accessibility of the fissures for cleaning and demineralisation. So it was suggested that the clinical identification of caries susceptible areas on occlusal surfaces should be based on the actual plaque accumulation (Carvalho et al, 1992). General plaque cleaning before the initial examination (preferably done by the patient) might help diagnose areas escaping the patients' regular oral hygiene procedures or due to reduced manual skills. Plaque disclosing would be the clue to areas susceptible to local risk factors, to which the following diagnostic steps are directed. Examples are areas where plaque is protected by a ditched filling or a crowded wisdom tooth Deep fissures and surface deficiencies might not be obvious unless the plaque is disclosed. Another disclosing method discloses acid producing active plaque, which is stimulated by a sweet rinse or sugar intake. A commercial alginate material (Clinpro Cario Diagnosis, 3M ESPE) is impregnated with such a disclosing agent where active plaque areas are coloured violet on the alginate impression. Thus the dentists can further refine their attention to the pathogenic cariogenic plaque where efforts should be directed.
2. Good dental unit light (Ekstrand et al, 1998). This doesn't mean that the light is only on, but means it is correctly directed to surfaces under examination. The practitioner should be familiar with the light's focus point and methods of deflecting light using the dental mirror.
3. Clean tooth. Experts may go to the extreme of recommending dental examination to be performed on totally clean surfaces after full mouth scaling and polishing. The merits for this are understandable but might not be affordable for each dental examination. For the occlusal surface, cleaning would remove materia alba, plaque and stains. Cleaning using a brush (Ekstrand 2001), probe (Ismail 1997), air-abrasive systems

(Banerjee and Watson, 2002) are recommended. For the later, care must be taken to control the amount of air pressure and force of abrasive particles to prevent damaging the tooth while performing the cleaning. Not all stains can be removed from the occlusal surface due to the complexity of the topography and adhesion of the stains. If the lesion is slowly progressing, then the stain might be incorporated in the structure itself during intermittent cycles of remineralisation in the dynamic carious process. Removal of all stains using air abrasive systems might mean minimal preparation of the tooth (Banerjee and Watson, 2002). This could only be justified where the dentist reached earlier the diagnosis of an active progressing lesion and had decided on a preventive resin restoration or fissure sealant immediately after the treatment plan approved by the patient. The term air polishing became more popular for devices that use sodium bicarbonate particles instead of the abrasive alumina particles and gemerally only remove plaque and stains.

4. Dry tooth: Soaked enamel with saliva has a light refractive index near to the normal dry enamel refractive index. Frosted enamel or opacities appear when pores between enamel crystals increase. The loss of minerals gradually increases the enamel porosity. If these were still small and filled with saliva then the refractive index is near to natural enamel and thus missed by vision (Ekstrand, et al 2001). Frostiness seen after 5 seconds of air-drying was found to be mostly superficial demineralisation (95%). Demineralisation visible without air-drying was mostly more deep but still without dentine demineralisation (Ekstrand et al, 1995a).
5. Good records: It might still be the job of the epidemiologist to detect the mere presence of caries in a number of teeth but not for the dental practitioner. The modern day management of the growing number of initial lesions lead the treatment options to shift toward pharmaceutical and preventive regimes. The ultimate efficacy of such decisions is associated with no further lesion progression. And because the signs of initial lesions occur on a relatively micro-scale, telltale signs of such activity should be carefully recorded and monitored. It may be even feasible to consider each fissure and pit as a single unit over the occlusal surface with each having its own degree of infection (Fejerskov and Kidd,

2003). Added to this is the fact that in-vivo studies that had produced significant remineralisation in initial lesions using conventional non-operative methods needed at least 2 years to prove this effect (Chester 2002, Marks 1994). If monitoring takes at least this long to see a difference, then clear and detailed records should be kept for these purposes as patient shifts between practitioners is likely to happen in this time span. Avoiding supervised neglect is a growing concern for practitioners who are under the close scrutinising supervision of the legally aware patients. This would clearly be avoided by having adequate records. Finally, changes that are associated with remineralisation do not always take the tooth back to its normal structure and shape. Stains do not disappear while the frosted appearance does. Drawings, intra-oral pictures, descriptive records can all be used.

6. Use of correct tools: a single correct tool for occlusal caries diagnosis was dismissed by the national institutes of health consensus development conference statement which was concerned with the diagnosis and management of dental caries throughout life. They stated in 2001 that "Observations and studies during the past two decades have indicated that diagnostic and treatment paradigms may differ significantly for large, cavitated lesions versus early, small lesions and demineralized areas on tooth surfaces. The essential anatomic-pathophysiologic problem is that the carious lesion occurs within a small, highly mineralized structure following penetration through the structure's surface in a manner, which may be difficult to detect using current methods. Additionally, carious lesions occur in a variety of anatomic locations, often adjacent to existing restorations, and have unique aspects of configuration and rate of spread. These differences make it unlikely that any one diagnostic modality will have adequate sensitivity and specificity of detection for all sites. The application of multiple diagnostic tests to the individual patient increases the overall efficacy of caries diagnosis".

What are conventional tools used for caries diagnosis. What outcomes should be refined by the practitioner using each tool.

1. Vision. It was thought that initial carious lesions occurring in the fissures are hidden in the walls of deep fissures. This was corrected by the work of Ekstrand and his team where he found that the maximum penetration of lesions in the narrow fissure-shaped grooves was, in more than two thirds of the cases, at the entrance zone followed by the middle part and few in the bottom. Whilst in the groove-shaped, around half of the cases were penetrating the most in the bottom part and some at the entrance with no difference in the depth between the parts. The clinical implication of this observation was important. The extent of the lesion could be detected by careful vision of the surface, as the narrow grooves would have most of the lesion at the entrance whilst the wide grooves were wide enough for the base to be seen. Furthermore, these lesions could possibly be controlled by regular brushing (Ekstrand et al, 1995; Ekstrand and Bjorndal, 1997a). In more progressed lesions, loss of enamel continuity occurs when there is loss of the dentinal support for the enamel structure, which fractures off because of its brittleness (Robinson, 2000). Localised surface destruction corresponded to superficial dentine demineralisation. Brownish discoloration with or without localised surface destruction had 50% of the cases with dentinal demineralisation (Ekstrand et al, 1995a). It begins small and increases with the advancing lesion front. This cavitation is associated with increased microbiological load in the infected dentine and becomes uncleansable (Ricketts 2002). However, in a study differentiating micro-cavitations where no dentine is exposed and frank cavitations with a dentine base, operative intervention was justified and validated microbiologically only if dentine was exposed in the floor or a radiolucency was apparent in the radiographs extending more than the outer third of dentine. These lesions seemed to be lightly infected (Ricketts et al, 2002). Down the line, it was only in advanced cavitated lesions where the lateral spread in the dentino-enamel junction was seen (Ekstrand et al, 1998) and none was seen in non-cavitated lesions (Bjorndal et al, 1999).

Excellent reviews, based on the understanding of this relationship between histological events and manifestation of lesions, reported on the high specificity of visual diagnosis (Ie and Verdonschot, 1994; Ismail, 1997). When translated to a clinical decision, this meant that teeth were safe from over treatment. However, the low sensitivity of vision to detect signs of early disease often lead to many decayed teeth to be left untreated (Wenzel et al, 1991), underestimation of caries prevalence (Lussi, 1996) and over-treatment with fissure sealants (Deery et al, 2000).

An early study found no significant correlation between the visual appearance of the site and the level of infection in the dentine. Furthermore, non-cavitated occlusal fissures, diagnosed as carious and required restoration, exhibited a range of visual appearances of which no particular feature was indicative of its condition, thus, visual examination alone was not helpful for deciding the treatment or preventive option for lesions (Ricketts et al, 1995a). This result was further tested and conclusions were contradictory as the external signs of caries were a good indicator of the degree of caries within the tooth. (Ekstrand et al, 1995a) and caries activity (Ekstrand 1998) (Table 1). These promising results would not have been achieved without implementing the optimal clinical conditions under which it could be performed and training the eye to the manifestations of early lesions. Combining other diagnostic tools was an option strongly recommended. (Ekstrand et al, 2001).

Score	Description
0	No or slight change in enamel translucency after prolonged air drying (>5s)
1	Opacity (white) hardly visible on the wet surface, but distinctly visible after air-drying (>5s).
1a	Opacity (brown) hardly visible on the wet surface, but distinctly visible after air-drying (>5s) .
2	Opacity (white) distinctly visible with out air-drying.
2a	Opacity (brown) distinctly visible with out air-drying.
3	Localised enamel breakdown in opaque or discoloured enamel and or greyish discolouration from the underlying dentine.
4	Cavitation in opaque or discoloured enamel exposing the dentine beneath.

Table 1 Clinical severity index scores (Ekstrand et al, 1998).

Does visual input need refining.

Yes. The signs picked by vision are: Frostiness, cavitation, colour and dimensions. There should be a refining mechanism for each outcome from other parallel similar changes accompanied by pathologies other than caries or as normal variations in tooth structure.

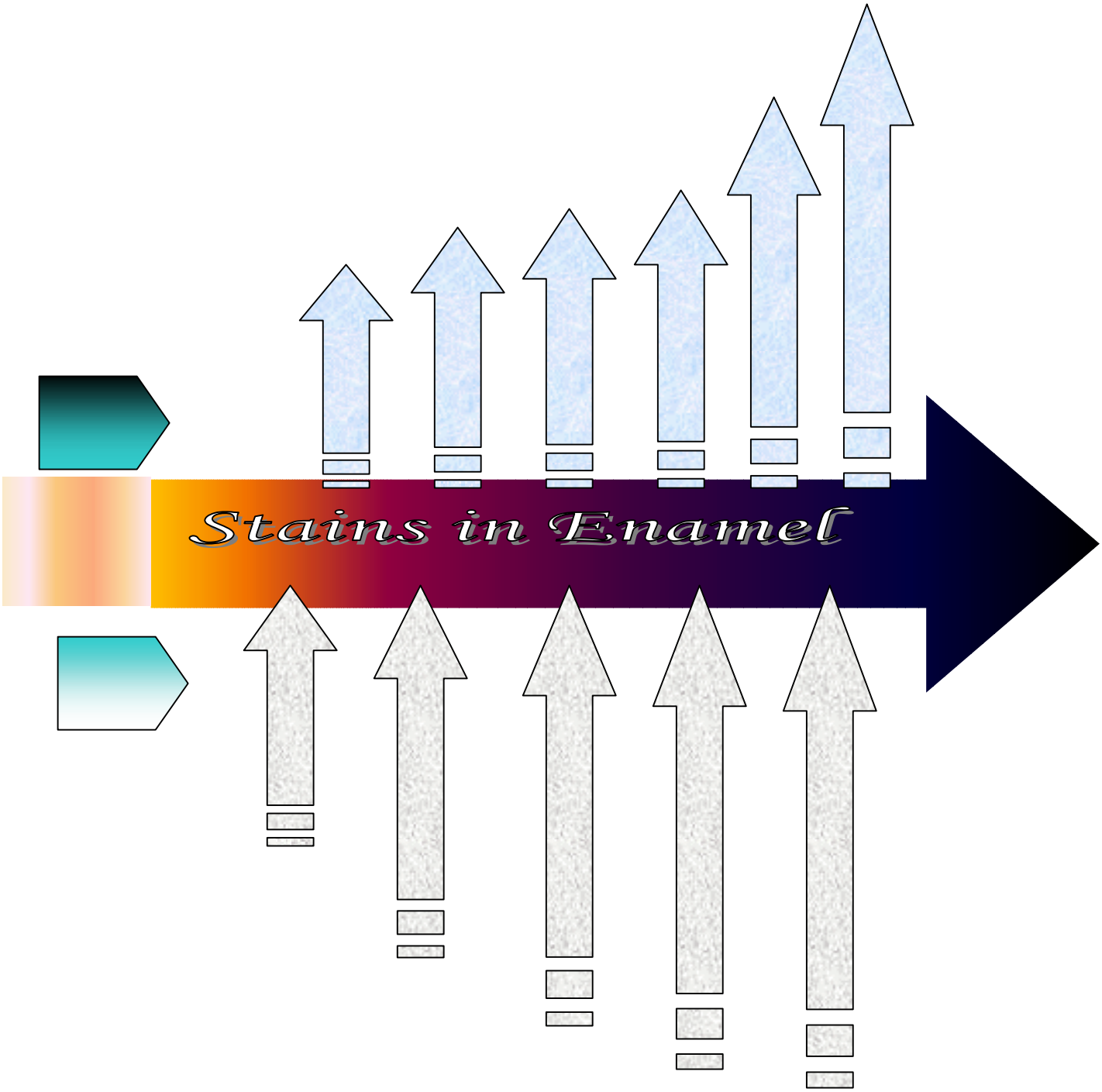

Enamel Cavities
Exclude
Dentine wear in occlusal facets
Chipped porcelain inlay
Ditched amalgam filling
Worn resin or GI filling
Missing/ lost filling
Enamel hypoplasia
Developmental pit
Iatrogenic
Add
Record if dentine shows in base
Dry the tooth for 5 seconds
Record size /mm2
Clean tooth
Use good light


Enamel Opacities

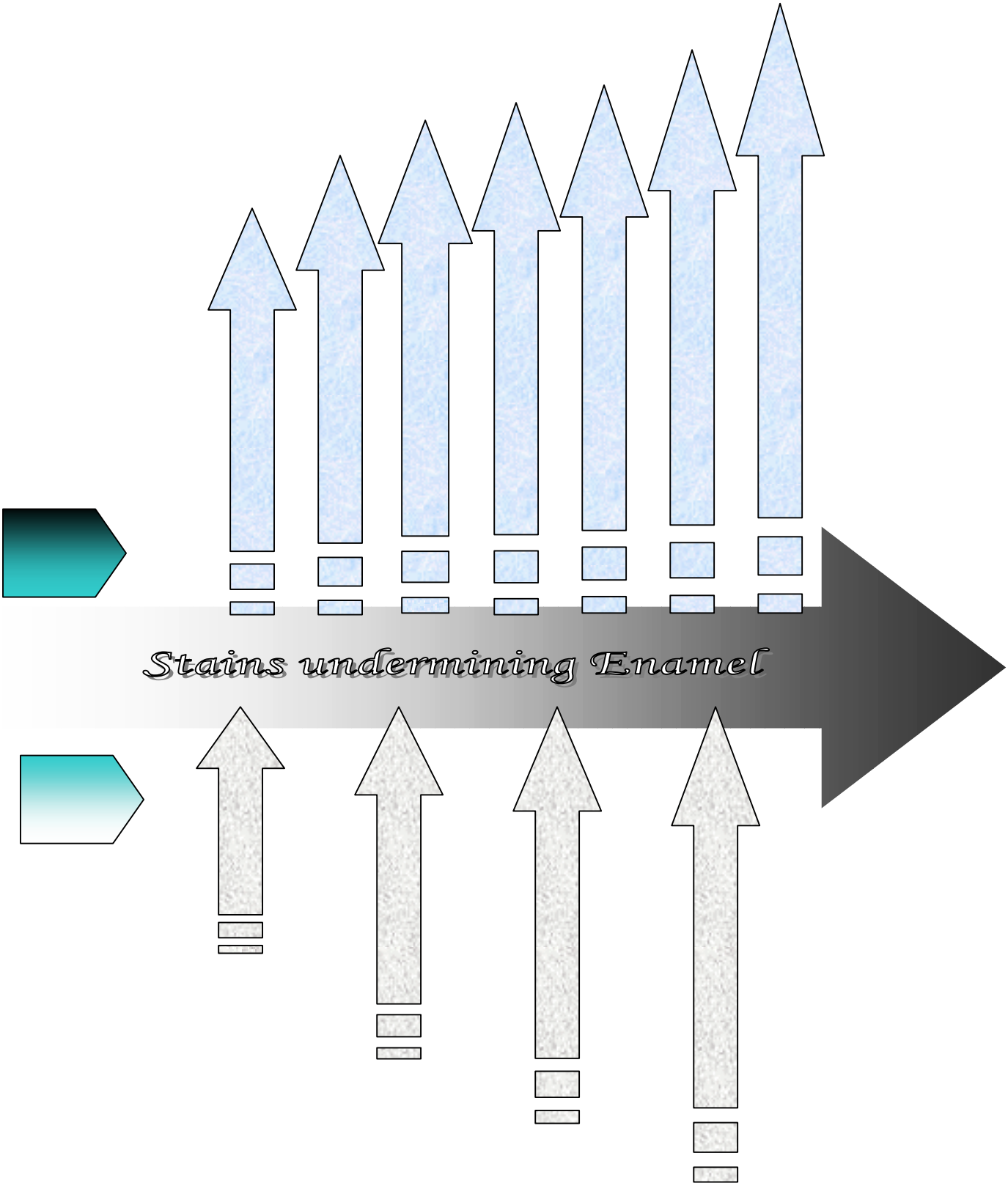
Stains undermining Enamel

Vision aids: Combination visual inspection of lesions with binocular magnification, radiographs and probes were studied (Lussi, 1993). As sensitivity and specificity of visual inspection were comparable with other studies, all combinations shared the low sensitivity whilst the combination of bitewing radiographs and visual inspection significantly improved the sensitivity.

Probe:

Studies in the last two decades began to question the regular use of probes for occlusal caries diagnosis. The probe didn't add to the sensitivity of vision, and even decreased the sensitivity of visual diagnosis (0.6 versus 0.65). In an in-vitro validation study of the sharp probe to detect fissure caries, sensitivities of 0.24 and 0.17 were found for caries stages at initial and deep stages (Penning et al, 1992). In a review, the probe was the least useful when listing available diagnostic systems in the diagnosis of early (non-cavitated) lesions in all surfaces except root caries (Dodds, 1993). Clinical examination was quite variable between practitioners owing to the size and shape of the explorer tip, the force applied, and the judgement of the examiner (Houpt et al, 1985).

When newly erupted third molars were probed unilaterally, 60% of the fissures showed signs of tissue loss, significantly lower than the 7% in the control group (Ekstrand et al, 1987). In a laboratory study, probing accelerated the rate of subsequent caries progression and possibly damaged clinically sound enamel and increased the chance for isolated lesion development. Initial lesions could be converted into cavities following probing with the size of the defect related to the pressure applied (Yassin, 1995). This might jeopardise the remineralisation ability of the previously intact lesion (Prinz et al, 1999). Probing was also thought to potentially spread infection to sound teeth but contradicting findings were published from the in-vivo study where the authors concluded that the inoculation by probing was not a likely cause for caries initiation (Hujoel et al, 1995).

All of the previous section results does not put the probe into retirement. There is still a lot for it to provide. In cavitated lesions, the information, which could be

gained, is enormous. The highest increase in the tools performances was noticed for the probe in cavitated lesions (Lussi 1993, 1996). Even for non-cavitated, the probe is still accepted for the removal of plaque from the fissures that might obscure cavities and to improve the access of direct vision. Care must be applied whilst using the probe not to produce damage by disrupting the continuity of the surface (Lussi 1996, Ekstrand et al, 2001).

The probes role in the last 5 years is gaining a new interest where not only lesions severity is diagnosed but also lesion activity. The same dragging motion used to clean the fissure using a blunt probe conveys to the dentist information about the surface roughness around the walls of lesions and an idea if the base is soft or hard (Nyvad et al 1999). Further results had showed arrested lesions became smooth and lost surface frostiness especially with regard to root caries (Lynch, 1996)

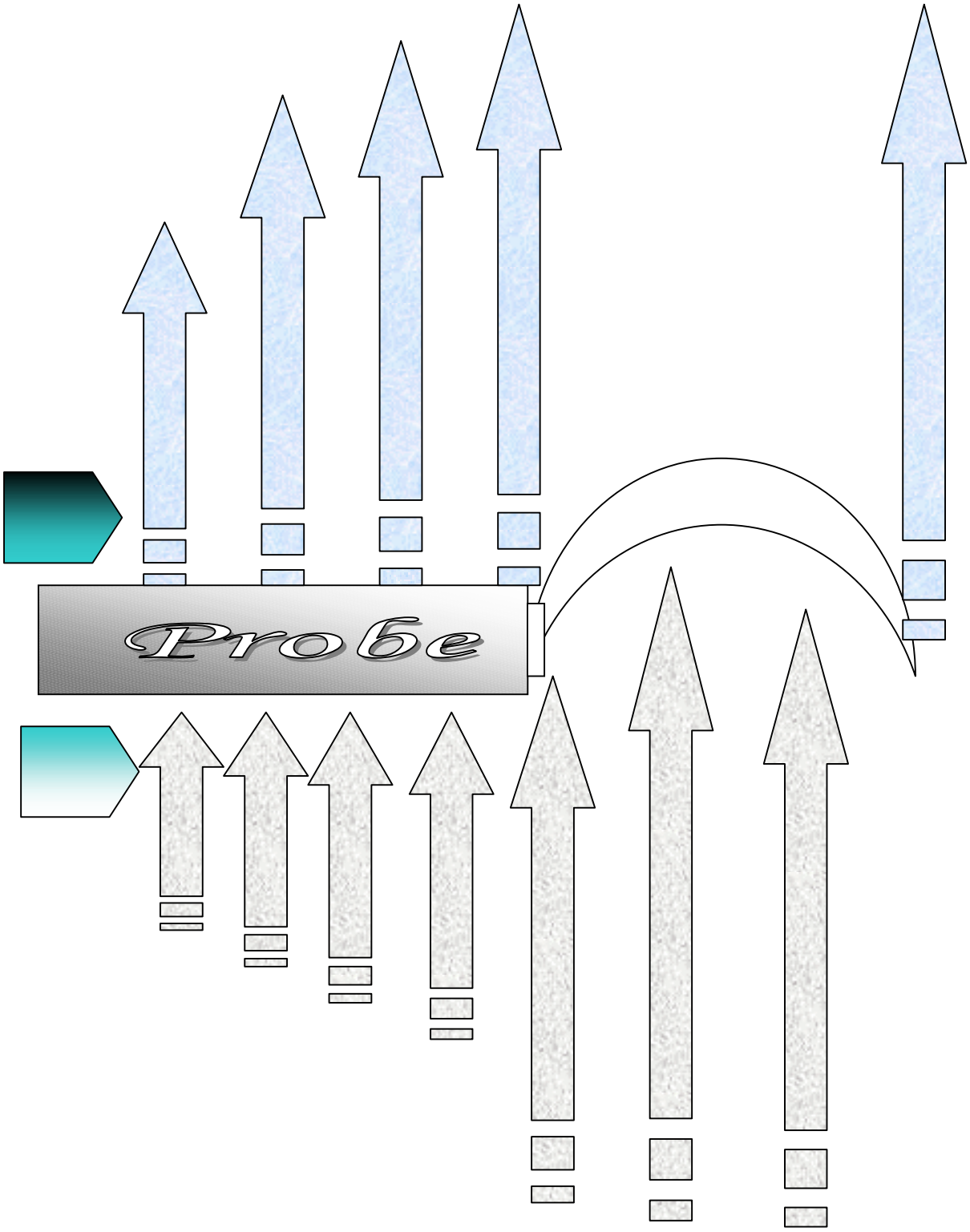

Radiographic diagnosis

The sensitivity of visual inspection was augmented with radiography. Findings on bite-wing radiographs were useful indicators of dentinal caries on occlusal surfaces, and it was well recognised that the prevalence of occlusal caries may have been underestimated without such imaging. In one study involving young air force recruits, only one-third of occlusal dentinal lesions were diagnosed visually, whereas two-thirds were discovered on bite-wing radiographs

(Richardson and McIntyre, 1996). Another study reported that bite-wing radiographs revealed obvious lesions into the dentine in 15% of apparently sound occlusal surfaces (Weerheijm et al, 1992). Of some concern was the significant number of 17- and 20-year-old patients who had received sealants but in whom later radiography revealed underlying radiolucencies; these findings suggest that the sealants were placed without prior diagnostic radiography (Poorterman et al, 2000). Of additional concern was the evidence that radiographs considerably underestimate lesion size. In-vitro experiments have shown that, once an occlusal lesion was clearly visible on radiographs, demineralisation has extended to or beyond the middle third of the dentine. On the other hand, false positives can occur with radiographic diagnosis, and specificities of 66% to 98% have been recorded (Ferreira Zandona et al, 1998).

Because of the superimposition of buccal and lingual enamel, caries of the occlusal enamel were not generally visible, and early dentinal involvement was difficult to ascertain with radiographs. In-vitro bitewing radiography alone resulted in a sensitivity of 58%, higher than that of visual inspection and a specificity of 87% according to histological validation (Ferreira Zandona et al, 1998). The use of digital contrast enhancement showed promise in improving the early radiographic diagnosis of lesions.

An investigation of the validity of diagnosis by a combination of bite-wing radiography with careful visual examination showed that the majority of carious lesions and nearly all sound teeth were correctly identified (Ketley and Holt, 1993). The validity of each diagnostic method (visual and radiographic), used separately and together, was investigated for extracted teeth with questionable or borderline caries. Together, these methods had a sensitivity of 75% and a high specificity (90%), thus reducing the risk of unnecessary operative intervention. However, the 75% sensitivity indicated that there remains a significant risk of missing early dentinal lesions.

Fibre-Optic Transillumination (FOTI)

Attempts to use transillumination to detect caries have been of value for approximal surfaces but have failed to provide additional information about the caries status of pits and fissures (Fejerskov and Kidd 2003)

The technique depended on the fact that carious enamel had a lower index of light transmission than sound enamel. For occlusal caries, a study compared fibre-optic transillumination (FOTI) with radiographic examinations and concluded that radiographic examination was a better diagnostic system than FOTI (Longbottom and Pitts, 1990). This was not the conclusion of other studies and was found to have a high predictive positive value (Verdonschot et al, 1992).

Laser Fluorescence (LF)

The LF method measured the fluorescence of the tooth that was induced after light irradiation to discriminate between carious and sound enamel. It was accepted that the induced fluorescence of enamel was lower in areas of reduced mineral content, and that there was a relationship between mineral loss and the radiance of the fluorescence. The term quantitative laser fluorescence (QLF) had been applied to the research method of measuring induced tooth fluorescence after using laser light generally at or near the 488 nm range to quantify tooth demineralisation and lesion severity. Several studies in which an argon laser light source (488 nm) was used to examine smooth enamel surfaces had shown a strong correlation between a decrease in fluorescence and the degree of enamel demineralisation (al-Khateeb et al, 1997). QLF was best suited for longitudinal diagnosis of early lesions of the enamel on accessible smooth surfaces, and many investigations had involved the monitoring of white-spot lesions (Emami et al, 1996), such as those observed in orthodontic patients during treatment and after de-bracketing.

In in-vitro studies of artificial and natural decay of occlusal fissure enamel, QLF had better sensitivity but poorer specificity than visual examination alone or

radiographic examination alone. QLF was affected to some extent by the wet or dry state of the fissure, by stains in the fissure and by fissure morphology. The use of air-polishing to remove plaque improved diagnosis by QLF (Ferreira Zandona et al, 1998)

Some reports suggested that QLF might have been limited to measurement of enamel lesions of at most several hundred micrometres depth and could not differentiate between decay, hypoplasia or unusual anatomic features. It also was not designed to discriminate between enamel and dentine lesions. Furthermore, the fluorescence from dentine was not related to dentine demineralisation, so this method was not suitable for measuring dentine demineralisation (Emami et al, 1996).

DIAGNOdent System

This is a commercial battery-powered quantitative diode laser fluorescence device. A fibre optic bundle directed onto the occlusal surface of a tooth produced light at 655-nm wavelength. A laser probe was designed for the occlusal surface to scan over the fissure area in a sweeping motion. The device displayed two values, the moment value for the probe position and a peak value recorded from the whole surface. DIAGNOdent had many advantages, as it was helpful where radiographs were not useful in early occlusal decay or when radiographs were refused by patients. It also gives instant feedback to both clinician and patient and involving them in the treatment decision. There are no known risks from use of the DIAGNOdent and it is also easily portable.

Diagnostic system	*n*	Mean Dz	± SD
Visual inspection	8	0.71	0.39
Fiber-optic transillumination	2	1.08	0.33
Conventional radiography	10	0.89	0.31
Digital radiography	8	0.97	0.27
Xero-radiography	1	0.73	0
Radiovisiography	3	0.91	0.15
Electrical Resistance Measurements	2	1.30	0

Table 2: Mean Dz values and standard deviations indicating the mean performance above chance from various diagnostic systems in occlusal caries diagnosis (le and Venderschot, 1994)

ECM

Carious enamel and dentine are more porous than sound tooth tissue and because they are filled with ion containing saliva fluids, they are less resistant to a small electric current (White et al, 1978). This was the principle behind the invention of an indirect way to measure the progression and activity of carious lesions, the ECM (Electric Caries Monitor).

Many studies were performed to adapt the principle of the electrical conductance property of the human dentition to the dental laboratory and clinical situations. These used many prototypes as well as commercially marketed caries detection machines, which not all are available today (Table 3). Nevertheless, there were significant differences in these devices such as various currents, measurements that had various relationships to the true conductance or resistance and caries severity, factors that had to be standardised by the operator, calibration procedure, air supplies, recommended cut-off points with their clinical inferences, validation outcomes, were exclusive to each device (Table 4). Therefore, all of those different factors affected the conclusions derived from those studies and limited the ability to cross compare absolute values in between studies that used different devices (Schulte et al, 1999).

Devices using the electrical conductance property of human dentition	
1	The modified AC Ohmmeter
2	Caries Meter L (G-C International Corp., Leuven, Belgium)
3	Vanguard Electronic Caries Detector (Massachusetts Manufacturing Corp., Cambridge, Mass., USA)
4	ECM I, II, III and IV (LODE Diagnostic, Groningen, The Netherlands)
5	Modified Electrochemical Impedance Spectroscopy (EIS)
6	Electrical Impedance Tomography (EIT)

Table 3: Examples of devices, which used the principle of electrical conductance property of human dentition as an indirect way to measure caries activity.

There were variations between the different studies because of the numerous different devices used and the number of altering factors, which could be standardised. An alternating fixed frequency current was used to monitor the behaviour of a suspect tooth spot after controlled drying conditions. Consequently, the resistance was determined only by the tooth volume, avoiding electrical leakage of the current through the low resistant surface fluid (saliva) film to the gingival margin. A probe was placed on a point in the occlusal surface (site-specific) and a connector was held in the hand of the subject or touching the gingiva.

Factors	Features
Device specifications	
Current used	▪ High or low frequency ▪ Alternate or continuous current ▪ Frequency of alternate current
Electrode	▪ Touching contra-lateral gingival tissue ▪ Touching contra-lateral the cheek ▪ Held by hand
Calibration procedure	▪ In lab using standard resistance units ▪ Internally calibrated
Air flow control	
Air supplies source	▪ 3in1 syringe before the measurement ▪ Connected to the tip and active during measurement
Direction	▪ Operator dependant ▪ Parallel to measuring tip
Air flow meter	▪ Supplied or not ▪ Could be altered or not
Air flow rate	▪ Stable flow or not, throughout the drying period ▪ Amount of flow rate per minute
Air flow time	▪ Time of application was variable
Air operation	▪ Automated or operator dependant
Measurement specifications	
Measurement display	▪ Numbers ▪ Symbols and Colours
Ranges displayed	▪ Small ▪ Large
Type of measurement	▪ Ordinal ▪ Continuous
Units	▪ Ω or none
Measurement procedure	

Number of measurements from each site	▪ one measurement ▪ multiple and the least single one was chosen ▪ multiple and the mean was chosen
Protocol for selection of the measuring site	▪ Most severe as detected by vision, ▪ Most severe as detected by the same other devices, ▪ Most severe as detected by device
Area of contact between measuring tip and tooth	
Area of contact with the tooth	▪ Tip area only (site-specific) ▪ Area of contact fluid (surface-specific)
Type of conducting fluid.	▪ Saliva of the subject ▪ Various tooth pastes ▪ Saline ▪ NaCl solutions
Area covered by the conducting fluid	▪ A single lesion area ▪ All fissures and pits. ▪ Including cusp tips and marginal ridges
Consistency of conducting fluid	▪ Fluid consistency ▪ Gel consistency
Visualisation of area covered by conducting fluid	▪ Possible by dyed fluid ▪ Not possible ▪ (transparent fluid)

Table 4: Various factors which might affect the validity outcome of the ECM as a diagnostic tool.

A modified AC Ohmmeter

This device was modified to be used for dental applications in in-vitro and then in-vivo studies. This device indicated the real component of the impedance (kilo ohm; KΩ) and employed an alternating current of a frequency of 500Hz and amplitude of about 1µA. The clinical device was modified to use a measuring electrode, which consisted of a dental explorer with a point-shaped tip (0.1mm in diameter). The grip was isolated with Teflon, leaving the tip uncovered at a length of 3mm. The second electrode was a metal sheet (2cm X 6cm), placed on the cheek mucosa, contra lateral to the tooth to be measured. Electrodes were connected to the Ohmmeter by cables. The device was used first in in-vitro studies aimed to measure the electric impedance of human dentine samples. The recorded values were found to vary with the orientation of the dentinal tubules. It was assumed that the mechanism underlying electric conductance in dentine was related to the transport of ions in the dentinal fluid (Gente and Becker-Detert, 1991a). This principle was used inversely. For a reading within a preparation, it was possible to estimate the situation of the pulp horn tips (Gente and Wenz, 1991b) and calculate the depth of the remaining

dentine in crown preparations or in standardised cavities (Gente and Haude, 1991c). As the impedance value recorded depends on the thickness of the dentine layer and the degree of tooth development, it was established that teeth of younger subjects had thicker dentine layers than those of older subjects for the same reading given.

Subsequently, it was proposed that different electrolyte concentrations affect electrical impedance of sound human enamel-dentine. Cylinders were stored for 24 hours in NaCl solutions with different concentrations. This was found to be true where the higher concentrations produced lower impedance values (Schulte et al, 1998).

An in-vivo cross sectional study used the device to compare caries free premolars in children and adults. Lower impedance values were found in children's teeth compared to adults. No significant differences were found between premolars in different (upper or lower) locations (Schulte, 1997). This was different from what was found to be lower resistance values for maxillary than for mandibular molars. The next longitudinal investigation was performed in children who had erupting premolars (Schulte et al, 1999). These were completely free of soft tissue but had not gained the occlusal height of the adjacent teeth. The electrical resistance values were obtained from the deepest point of each mesial and distal part of the fissure after saliva was dried and cotton rolls isolated the tooth. The fissures were then carefully moistened with a small drop of distilled water and second measurements were recorded. Next, the tooth was dried with a cotton pellet and a small drop of physiological saline was placed, and the last measurement recorded. The procedure was repeated every 3-6 months. The mean resistance values were found to increase continuously from the eruption up to the 13-15th post eruptive month then stabilise for up to 24 months. The NaCl produced the lowest resistance values followed by distilled water, then saliva-coated teeth, which had briefly been dried. Some children, who had a history of fluoride intake as tablets for many years, had erupting teeth that exceeded a value of 1000KΩ. After 15 months, all measured values were over this cut-off point (Schulte, 1999).

This study had not included any molars. However, it was suggested that previous work had found that the molars, especially the wisdom teeth , needed more time to mature. No specific time was given. A later study on molars found maturation to be over a period of 36 months, where conductance values decreased by a factor of 2.2 over that period (ten Bosch et al, 2000). The reasons for this were not clear. Molars were known to have structures that were more complex over a larger surface area, which take more time to clear from the surrounding soft tissue and have extensive fissure systems with more cracks and defects. The 3 seconds may not be enough for drying the teeth. Furthermore, there seems to be a difficulty in seeing clear solution on teeth surfaces and in controlling it not to leak out of the occlusal surface. For recently erupted premolars, there was the possibility that the developmental grooves on the lower second and the mesial of the upper first premolars can cross the marginal ridge causing capillary action driving crevicular fluid to reach the tooth and the conducting media over it to leak out to the gingival margins.

The same device was then used to measure differences between bovine and human enamel (Schulte, 1999). The human enamel was reported to have higher resistance values, under different test solutions, than bovine enamel. Thus, electro-physical differences between species must be accounted for when using bovine enamel in dental material and chemical studies.

Caries Meter-L

The Caries Meter-L had been reported to be manufactured by two companies; G-C International Corp., Leuven, Belgium (Ricketts et al, 1995b) and Onuki Dental Co. Ltd., Japan (Huysmans et al, 1998b). A 400Hz current was used. The display was in the form of four coloured lights reflecting the status of the tooth; green for no caries, yellow for enamel caries, orange for dentine caries, and red for pulpal involvement. Calibration in the lab employed a standard resistance box between the probe tip and oral electrode. Values were recorded each time the light's colour changed. Values were different amongst studies (Ricketts et al, 1995b; Sawada et al, 1986) (Table 5).

The measurements on teeth were taken between a probe tip and a clip attached to an oral electrode. The teeth were dried by the 3-in-1 syringe and isolated by cotton rolls then required re-moistening with a drop of saline. Measurements were between site-specific and surface-specific readings, as the drop would spread on the surface without any control other than what was dictated by the fissure or pits pattern (Ricketts et al, 1995b; Huysmans et al, 1998b). Sensitivity of this device was 74% and the specificity was 74% at the enamel caries level (D1), whilst 93%, 63% at dentine caries level (D3) (Ricketts et al, 1995b). Although good inter-examiner repeatability was found, there was a difficulty putting a specific cut-off point for the best performance (Huysmans et al, 1998b). The information obtained from the device was insufficient for many reasons. Restricting and standardising the flow of air to dry the tooth (Ricketts, 1996b) and the area of saline contact medium (Huysmans et al, 1998b) made the technique less favourable than that employed by other machines. Furthermore, the transformation of the continuous scale changed to an ordinal scale display of 4 categories presented by colour and may not be able to follow-up small changes in the resistance of tissue brought about by the remineralisation or continuous demineralisation, limiting the ability of the device to monitor lesions longitudinally.

Colour	Resistance value at the point of colour change	Resistance value at the point of colour change
Green	>1.41 Ω	>0.6 Ω
Yellow	0.37-1.37 Ω	0.25-0.6 Ω
Orange	0.01-0.37 Ω	0.015-0.25 Ω
Red	< 0.01 Ω	<0.015 Ω
Study	Ricketts et al, 1995c	Sawada et al, 1986

Table 5: Resistance value ranges, which correspond to the points where each of the displayed light's colours change, when using the Caries meter-L.

The Vanguard electronic caries detector

The Vanguard electronic caries detector overcame the inconsistency in the direction and flow rate of air. The probe tip was placed centrally and coaxially within a stream of air so that when the probe was placed in the fissure, superficial saliva was removed whilst taking the reading (Flaitz and Hicks,

1986). The conductance measurements were made between a specially designed probe tip and a hand-held connector. The frequency of the device was an alternating square wave voltage of 25Hz frequency, which was able to produce a low current of approximately 3µA. The readings were, therefore, site-specific.

The machine displayed a frowning face that indicated extensive demineralisation or the smiling face that indicated a sound site. Readings of whole numbers (0-9) were inversely related to the resistance and indicating increasing degrees of demineralisation. The scale was thus an ordinal conductance scale. This also limited the ability to detect small changes in longitudinal studies. A bar chart indicated the stability of the reading. The device was set to display the final reading when it had remained stable through continuous drying for three consecutive seconds. The airflow continued to dry until a point was reached where all external moisture was removed and the tooth's status was dependant on the hydration by the wet dentine through the pores of demineralised enamel. Therefore, various drying times were needed to reach a stable reading in lesions with different severities and it was not possible to standardise between studies or between the different teeth within the same study (Ricketts, 1996b). One, two or three readings were taken for each tooth and the mean calculated. The subject was asked to re-wet the tooth between readings. The site chosen for the measurement was the most severe as seen clinically (Verdonschot et al, 1993), or measured by the device itself (Rock and Kidd, 1988). The calibration of the Vanguard was done with a standard resistance box. There was an inverse logarithmic relationship between resistance and the Vanguard conductance scale (Ricketts et al, 1995b).

A cut-off point was placed at a mean ECM value of 2 ± 0.4 to distinguish sound or caries in enamel or dentine (D1) and 6 ± 0.5 to sound (or minimal enamel caries) or dentinal caries (D3) (Flaitz and Hicks, 1986). The second point was the same cut-off point found in a later longitudinal study during the course of 18 months (Ie et al, 1995). Consequently, sites that had an ECM value of 6.5 or higher, measured within 6 months after eruption, had an increased probability of developing dentinal caries. This indicated that the ECM could be used to predict

the need for a sealant or sealant restoration within 18 months after baseline. A strict cut-off point (8 to 9) was applied in an in-vitro study (Verdonschot et al, 1993), where it was suggested that this strict point was chosen because measurements were already taken in areas where a lesion was suspected. This point was later used in an in-vivo study (Ie et al, 1995). The last cut-off point was 3 to 4 used in a study, which further concluded that in-vivo and in-vitro readings on the same teeth with this device were comparable. Sensitivities reported using this device in-vivo ranged from 80% to 97% (Ricketts et al, 1995b; Rock and Kidd, 1988; Ie et al, 1995; Verdonschot et al, 1992).

Specificity was less acceptable, ranging from as low as 43% up to 89%. If false positives due to incomplete drying of the teeth were excluded, the majority might have been by recently erupted, less mature and highly porous enamel or by readings obtained immediately after eruption, incomplete clearance from the operculum, or the interpretation of a deep fissure system reaching into dentine as a lesion (Rock and Kidd, 1988; Ie et al, 1995). A period of 2 to 3 months was recommended by one study for a tooth to achieve the maturity (Flaitz and Hicks, 1986). This was not the case in previous studies using the modified Ohmmeter, which found it to be 15 months in premolars (Schulte et al, 1998) or to continue up to 18 months in molars (Ie et al, 1995) with no indication to what was the end time when full maturation was achieved. The site from which the readings were taken affected the overall performance of the device. Therefore, it was considered essential to search the surface by taking more than one reading per tooth. The specificity was higher for enamel caries level (D1) than for dentinal caries level (D3) (Ricketts et al, 1995b). This showed that the device was valuable in measuring early lesions, as the porosity produced in enamel was responsible for the main drop in the resistance values and the dentine was markedly less resistant to the electric current. It was stressed that a single reading at one visit may not be able to measure the activity of the lesion. Only when lesions were monitored longitudinally, it becomes possible to detect the change towards remineralisation, demineralisation or stabilisation.

A longitudinal study used another approach to study performance of diagnostic and predictive tests, which does not calculate sensitivities and specificities, but applies a

qualitative approach, i.e. survival analysis (Fennis-Ie et al, 1998). The main diagnostic tool was visual inspection. 81% of the sites, which had a baseline ECM reading of 5-9, developed caries extending into enamel or dentine (D1) within 2.5 years. An ECM reading of 9 had the highest validity when it came to the diagnosis of dentinal caries, as 28% of the sites with an ECM reading of 9 showed dentinal caries (D3) within 2.5 years compared to 3% of the sites with an ECM reading of 0-8. ECM was a better predictor of caries than visual inspection and Fibre Optic Transillumination (FOTI).

The ECM by LODE Diagnostics

The ECM by LODE diagnostics took a long path by which many versions were tested. At the time of this report, the 4th version was available.

Prototype I

The first prototype (Prototype: P. Borsboom Sensortechnology and Consultancy, Westererriden, The Netherlands) used a design close to the Vanguard machine. An airflow gauge was included in the device. The airflow through the tip was at a changeable rate, which could be changed from 5 to 10L/min.

The conductance measurements were made between a tip placed on a hand piece and a hand-held reference electrode. A battery-driven alternating sinusoidal wave voltage was employed (frequency of 21Hz). Readings were also site-specific. The continuous resistant values were converted once more to a conductance scale. This time, a logarithmic relation to the third power function existed between the original resistance readings and the conductance scale (Huysmans et al, 1995).

$$\text{Log} = -0.002196\ \text{ECM}^3 + 0.042114\ \text{ECM}^2 - 0.37869\ \text{ECM} + 4.5341$$

The ECM reading appeared on a screen on the front of the device. It can be positioned in a range of about -1.00 to 13.00, representing increasing electrical conductance. These were continuous with two decimal places. A higher reading meant more decay. For purposes of comparison between devices, some

studies suggested further change of any negative value to zero and any value over 9 to 9. Any fractions were rounded out to the nearest integer (Ie et al, 1995). Repetition of readings at the same visit was indicated; other studies seemed to use one reading. Calibration was done according to the manufacturers instructions by comparing the display of the device to three known resistance values (1.00, 3.3 and 6.8 MΩ) (Lussi et al, 1995).

The device was set to display the final reading when it had remained stable through the drying period. In this manner, it was not possible to standardise the procedure between studies or within teeth in the same study. The threshold for dentinal caries according to the manufacturer's instructions was about 6.00, if the ECM was used in the normal, scanning method (Huysmans et al, 1998b). The reporting of clinical implications of resultant readings was variable. A reading of 6.5 was put as the cut-off point differentiating either dentinal lesions or sound and initial enamel lesions (Ie et al, 1995). The sensitivity of this cut-off point when measured on teeth, which had erupted for not less than 6 months, was 68% and specificity of 65%. After one year the sensitivity and specificity were 86% and 77% respectively. At 1.5 years, the sensitivity was 100%, and specificity was 50%.

Another study aimed to put four categories used the manufacturer's range and interpretation (Table 6) (Lussi et al, 1995).

Range	Clinical interpretation
1.00 to 3.00	Sound enamel or early stages of caries
3.01 to 6.00	Caries up to the DEJ (enamel caries)
6.01 to 8.00	Dentinal caries
8.01 to 13.00	Deep dentinal caries

Table 6: Clinical interpretation of value ranges measured using the ECM prototype I.

An accuracy of 63% was found compared to 83% when a 2-point classification was used (no dentine caries/dentine caries present) and there was the

possibility of 13% - 44% of the sound teeth treated invasively (Lussi et al, 1995). This low specificity could be reduced by three methods. First, lowering the threshold value (D1) where enamel was considered as a positive outcome from histology. This increased the sensitivity to 96% and the specificity to 100%. Second, lowering the threshold for caries diagnosis (D1) and lowering the cut-off value on the device to 1.74. The discrimination between sound and carious sites was more specific (96%) whilst still sensitive (61%) (Ricketts et al, 1997a). Third, changing the airflow to 7.5 or 10 Litres / minute (L/min). This produced the best sensitivity and specificity under the ROC curve for all diagnostic thresholds (D1&D3) (Ricketts et al, 1997c). The ability of the device to detect small changes improved in longitudinal studies, as there were more categories in the continuous scale.

The method where the surface was to be measured at more than one point was found to be time consuming. To overcome this, in-vitro studies were performed to improve the readings and take an overall surface value by applying a conducting gel to the dried and cleaned surface. The measuring tip was placed over it with no air during the measurement. The first study aimed to investigate the effect of the increase in the surface area and the conductance value (Huysmans et al, 1998b). It was a linear relationship between conductance and enamel electrode area in all teeth. The slope and intercept parameters were significantly different for teeth with complete and incomplete root formation and suggested that the enamel may take more than 1 year to mature fully. A further reduction in resistance values was possible on the occlusal surface measurements in comparison to smooth surface measurements due to many reasons. The irregular occlusal surface in the 3-dimensional (3D) was larger than its two-dimensional projection. Molar teeth have a larger 3D area than premolars for the same 2D area, when measured from a 2D picture. Furthermore, the enamel thickness in fissures was very irregular. Buccal smooth surface enamel had factors that may have further reduced the readings. Some of these were macro and micro-cracks together with a shorter intra-oral period for maturation. Raising the threshold for diagnosing dentinal caries through surface conductance measurements compared with site-specific

measurements and using different values for molars and premolars was recommended.

A moderate to good linear correlation between histological lesion depth and electrical surface-specific conductance measurements was found (Huysmans et al, 1998a). The accuracy of the surface-specific measurements was different for the threshold level (D1 or D3) and the teeth measured (molars or premolars). Conductance values were lower for premolar teeth, which were smaller in area than molars. Surface-specific technique was better for detecting dentine lesions and reduced the need for experienced operators, as the reproducibility was very good. However, premolars had lower performance in comparison to molars. The cut-off point recommended for premolars was 507kΩ and for molars 233kΩ (a reading of 10.1 and 11.5 respectively). Using this technique, an interesting finding was the variation of conductance readings with the season of observation: In the fall, the resistance was lower than in the spring for the same molars studied. Nevertheless, there was no mentioning of a need to change cut-off points at those times (ten Bosch et al, 2000).

The principle was further extended to measure marginal leakage around fissure sealants in-vitro (Verdonschot et al, 1995). The fissure sealants were applied in three different ways to insure a non-leaking sealant, a leaking sealant and a leaking restoration. The teeth were thermo-cycled and then validated by histological sectioning and dye application. The area under the ROC curve for the diagnosis of a marginal leakage into dentine was very high (0.96). The cut-off point for leaking and non-leaking sealants was found to be within a range of 7.07-10.83. This performance was yet to be analysed for many factors, which were not studied, as different cut-off points recommended for different teeth and various restorations as well as the validation of such points. The performance of an application in the clinical situation was still to be considered.

In general, there was no standardisation for the gel used (ion concentration), the drying time before the gel application or the anatomical features included in the gel area (as oblique ridges, marginal ridges or cusp tips).

E*CM II*

ECM II (ECM II; LODE, Groningen, The Netherlands) was used in many studies. This was battery-driven. The probe tip was in the centre of an air tube of internal diameter 1.8mm and had a diameter of 0.46mm. A flow metre linked to the air supply was *integrated* so that the airflow around the probe tip could be adjusted. Air supply was from the dental unit via a coupling to the air rotor lead and activated by a foot control pedal at a flow rate of 7.5mL/min. The scale was also continuous and inversely related to the resistance placed between the probe tip and hand-held connector but didn't follow the logarithmic relation to the third power function which existed in the previous prototype. Different ranges were reported by different studies. These were -0.45 to 13.25 (Ekstrand et al, 1997a); -0.64-13.25 (Pereira et al, 2001); and -1.0 to 13.0 (Verdonschot et al, 1995). The provision of the extended scale to 13.25 to include low resistance values, would act to permit the progress of dentine lesions to be monitored (Ricketts et al, 1997b). An audible bleep indicated that the circuit was completed between the probe tip and the hand-held connector. A double bleep indicated when the stable conductance reading was reached. A carious lesion confined to enamel depends on the degree of porosity and lesion depth. A shallow enamel lesion with a small pore volume will dehydrate rapidly, whilst a lesion with a larger pore volume will take longer to dry out. This dynamic situation resulted in that the conductance continually changed until a stable conductance value was attained (Huysmans et al, 1998a). Calibration of the device was attained once more by a standardised variable resistance box.

There were no significant differences found in an in-vitro study between the stable conductance readings and cumulative resistance measurements in terms of validity (Ricketts et al, 1997a). However, stable conductance readings were more repeatable in a shorter clinical time. As the airflow was tested, all measurements taken at airflow rate of 5 L/min produced low specificity values in comparison to flow rates of 7.5L/min and 10L/min (Ricketts et al, 1997b). This might have been caused by insufficient elimination of surface moisture. 7.5 L/min was found to be the least airflow rate to eliminate the false positives. It also was found to have a moderate-to-strong direct relationship with depth of lesion from the surface or DEJ and an inverse moderate-to-strong relationship with the mineral content in enamel at the dentine caries threshold (D3). At only

the enamel caries threshold, mineral loss in enamel was more relevant to resistance values than lesion depth. This reflected the complex pattern by which these lesions occur. This strong correlation between the ECM readings and the depth of the lesions was confirmed by another in-vitro study and was validated histologically. Sensitivities ranged from 82-95% and specificities from 82-87% for various investigators (Ekstrand et al, 1997a). It was then followed by an in-vivo study reaching the same conclusion (Ekstrand et al, 1998). However, it was stressed that the ability of this device to monitor the activity of lesions should be further studied, as the sample was not representative in this investigation.

Different cut-off points were recommended depending on the airflow, the caries threshold, the type of reading (site or surface-specific), the type of gel used, the study performed (in-vivo or in-vitro) and the unit of measurement used (Ricketts et al, 1997a). Further variation should be accounted for e.g. sample population (molars or premolars), caries prevalence within the group, the fluoride intake by individuals, the intra-oral age of the teeth, the state of other teeth and oral hygiene (Ekstrand et al, 1998).

In-vitro, for site-specific readings, at the D1 threshold, the cut-off points for airflow rates 5, 7.5, 10L/min were 12.45, 1 and 2.55 respectively. At the D3 threshold, the cut-off points for airflow rates 5, 7.5, 10 L/min were 12.69, 5.28 and 4.18 respectively (Ricketts et al, 1997b). In addition, another found cut-off points for dentinal caries (D3) were 6.00-6.01 (for site-specific readings) and 10-11 (for surface-specific readings) whilst using 7.5L/min. For enamel and dentinal lesion (D1), these were –1.01 to 0.00 and 8.00 to 8.01 in that order. These lower cut-off points were recommended to aid in the decision to invasively open fissures at sealing time. Another cut-off points was given in a range of 2 to 3 and 3.1 to 12 on the ranked score system described earlier (Ekstrand et al, 1997a), and the same was used for the in-vivo study (Ekstrand et al, 1998).

A cut-off point of 9 or over was considered for dentinal caries as the gold standard in an in-vivo study against which the performance of two other diagnostic devices were compared (Thomas et al, 2001). No difference in the

performance was found between bitewing and panoramic radiographs for the diagnosis of occlusal dentine caries. The significance of this study was it was the first to use the device as a gold standard for in-vivo studies.

There was another name reported; ECM type IIb (P. Borsboom. Sensortechnology and Consultancy BV. Westerernden. The Netherlands). It consisted of a probe tip connected to an alternating current supply (sinusoidal waveform, 21Hz). The digital display panel gave a resistance measurement on a scale 0-2 MΩ. No mentioning of calibration or airflow was done in the available published literature. A conducting medium was used to obtain a surface-specific reading. An in-vitro study used extracted teeth with little control on factors affecting the readings prior to extraction. The optimum sensitivity and specificity values obtained for the surface-specific readings at the D1 and D3 diagnostic threshold were 61%, 86% and both 76% in that order. The resistance cut-off value used to achieve this was 0.448 MΩ and 0.419 MΩ where a diagnosis of a sound site being indicated by a reading at or above these figures. It was stated that these cut-off points might be different for various gels used and this must be taken into consideration when comparing different studies. Electronic resistance measurements performed better on molars than premolars at the D1 threshold level whilst it was not significant at the D3 level. It was concluded that this method might be useful in epidemiological studies and clinical trials (Ricketts et al, 1997a).

Another in-vitro study found the ECM to be the most valid and repeatable method used for enamel and dentine caries. Cut-off points were used for surface-specific readings as in table 7 as recommended for ECM IIb (Ashley et al, 1998).

.

Clinical implication	Range
Dentinal caries	0.000 to 0.390 MΩ
Enamel lesions	0.391 to 0.501 MΩ
Sound tissue	> 0.501 MΩ

Table 7: Cut-off points and their clinical implications as recommended for ECM IIb.

Then it was suggested to change enamel lesions (D1) cut-off points to 0.291 and dentinal lesions (D3) cut-off point to 0.10. This was found to increase the specificity whilst still minimally lowering the sensitivity and keeping it superior to other methods tested. However, it was stressed that further work must be done to assess the cut-off points for clinical situations separately and that recommendations for invasive treatment decisions depending on these points were to be taken with caution, as the specificity was low in comparison with other devices (Ashley et al, 1998). In-vivo, the same method was used and this time the air-drying was standardised to 20s blown from the 3-in-1 syringe (Ashley et al, 2000). The ECM predicted carious lesions within a good sensitivity and specificity (0.75 and 0.78 respectively). However, from lesions, which were scored at baseline as carious, only 21.9% developed visual signs of caries and 23%, were detected as sound after 18 months. The reversal of lesions was a possible explanation of the second percentage whilst further maturation of surface enamel was excluded by the age of the sample. The actual validation recommended for these findings, visual examination was the primary outcome against which these values were calculated.

ECM III

ECM III was reported to have been used in different situations. An in-vitro study used deciduous teeth with macroscopically intact surfaces (Francescut and Lussi, 1999). Two electrical caries monitors (ECM II and ECM III) were compared with other diagnostic method sat two levels, caries involving more than half of the enamel thickness (D2) or caries involving dentine (D3). Both had high specificities (100%). However, the sensitivity values were lower at the D2, 31% (ECM II) and 34% (ECM III), whilst at the D3 level they were higher for both, 58% (ECM II) and 52% (ECM III). A second study used permanent teeth (Deery et al, 2002). A moderate agreement was found with both monitors and sensitivity at the D3 threshold was considerably lower for the ECM II compared to the ECM III. Another study found that the ECM did not provide increased accuracy over visual diagnosis of lesions in primary teeth (Ashley, 2000).

The effect of altering the protein content of enamel or etching the surface was studied. It was found that the ECM resistance readings decreased as the concentration and time of de-proteinisation (by sodium hypochlorite) increased. The acid etching reduced the resistance readings as well. Brown lesions were more resistant to both procedures than sound and white-spot decayed samples, in that order (Huysmans et al, 2000). Various sodium hypochlorite solutions have many pH values and many concentrations. The reduction of the solution to an acidic level (pH = 6) increases its efficacy as an antimicrobial agent (Rutala and Weber, 1997). Furthermore, at different concentrations, sodium hypochlorite lowers the pH value at the tissue level (Spano et al, 2001). These, combined, might explain the reduction of the ECM resistance as an acidic effect with the de-proteinisation one.

It was then used it to monitor lesions demineralisation (Yeganeh et al, 1998). It was found that the *integrated* value was inversely related to lesion depth and mineral loss in both enamel and root samples. It was also inversely related to the time of demineralisation, which extended for 4 weeks. The mean change for the enamel samples was higher than the mean change for the root samples at all time intervals. It was concluded that the ECM was valuable in monitoring early demineralisations in artificial caries studies.

A comparison was done on the caries removal using Carisolv and conventional slow-speed rotary instruments (Moran et al, 1999). Single lesions were cut in half and then assigned to one of the treatment groups. The ECM gave mean values for both groups that were not statistically different and it was concluded that chemical excavation with Carisolv was as effective in removing carious tissue as conventional drilling.

Remineralisation using toothpaste was monitored in-vitro (Petersson et al, 1998). The mean value of the ECM readings increased as the time of soaking in the toothpaste increased. Enamel samples had a mean change that was larger than the mean change for dentine samples. Further applications were

suggested to compare different toothpastes. Validation was recommended for these procedures.

Root caries was tested using the ECM in various ways. The ECM readings were compared to clinical classification criteria for root caries (Lynch et al, 1999). Soft dentinal lesions and dark brown lesions had a lower mean *integrated* value than leathery lesions and light brown lesions respectively. Another study found that root caries generally had low resistance values. The ECM gained a good reproducibility by different operators. It correlated negatively with histological lesion depth and positively with remaining thickness of the dentine bridge (Wicht et al, 2002). A longitudinal study found earlier that the ECM could detect the deterioration of root lesions in-vivo (Yeganeh et al, 1997). Probing was found to break the superficial layer over a root lesion and predisposes to further demineralisation and cavitation. The ECM was able to demonstrate this as the mean resistance value for probed lesions related to further demineralision (Prinz et al, 1999).

ECM IV

Version IV used AC power supply by an adapter to 50Hz - 15 volt AC (Lode Diagnostics manual, 2000). It worked on a low frequency of 23 Hz and a current < 0.3 µA. Air supply was through a coupling to the air rotor lead and activated automatically once there was electrical contact between the measuring and reference electrodes. The probe tip was situated in the centre of an air tube. A flow meter was provided separately to check the air supply on installation. An internal component allowed the airflow around the probe tip to be altered. The flow rate was set to 5L/min and this could be changed to 7.5L/min when using the Vanguard measurement method. There was a connection and a software programme through which readings were sent to a personal computer. Additional records could be kept in it for each subject with clinical findings and ECM recordings. An internal reference precluded the need to calibrate the device. The investigator had to regularly perform a total function control.

The readings appeared by three procedures. The operator could choose each according to the purpose of the study performed.

Position 0 used the “Vanguard Procedure”. This was similar to the Vanguard machine used previously. Once the circuit was closed, the start of the drying was indicated by an audible signal (one beep). The measuring time was determined by the behaviour of the lesion during the drying period. When the resistance change was within a stable range for 3 seconds, drying stopped (a double acoustic beep was heard). Two values appeared: the first was whole numbers ordinal conductance scale (0-9), which was inversely related to the resistance and indicated increasing degrees of demineralisation. The second was the measured resistance value (*End value*). Cut-off values recommended are present in table 8.

Clinical implication	Range	Cut-off points
Sound enamel	0 to 2	>l GΩ to 10.0 MΩ
Initial Caries	1 to 3	17.0 MΩ to 4.00 MΩ
Caries up to DEJ	3 to 7	6.00 MΩ to 1.50 MΩ
Caries passed DEJ	6 to 8	2.00 MΩ to 1.00 MΩ
Deep dentine caries	7 to 9	1.50 MΩ to 0.20 MΩ

Table 8: Cut-off points and their clinical implications as recommended for ECM IV (Vanguard values).

Position 1 used the "Continuous reading" procedure and did not apply air-drying. The display showed the actual resistance value measured. This allowed for surface scanning within a wet or 3-in-1 syringe dried tooth. Difference between areas within the same tooth could be compared. This also could be used for the surface readings with the gel.

Position 2 used the “Standard ECM Scale” procedure. The total drying and measuring time was fixed at 5 seconds. The airflow was fixed at 5 L/min using an adjustable pressure reducer in the electronic unit. At the end of the measuring cycle, the *Integrated* Resistance value, in ohm second units (Ωs), across the total 5 seconds of drying was displayed. The second alternating value was the mean resistance value of the last second of drying (the *End value*) in ohm units. Higher readings indicated higher resistance and more caries. Three to five readings were recommended for each lesion (centre, north,

south, east, and west). The tooth was re-wetted by saliva, in-vivo, at least 5 seconds between successive readings.

Here, ranges were recommended rather than cut-off points, and it was stated that the ECM sensitivity was optimal at around 2.5MΩ, *end value*, where the lesion was up to the enamel dentine junction. Sound enamel were around *End value*s in the area of > 10MΩ up to > 1GΩ, which depended on surface quality, structure, maturation and others. Deep lesions had *end value*s around 150kΩ. Processes such as erosion, early de- and remineralisation, and after excavation showed *end values* between 500 - 1MΩ. The importance of this measurement was in it's use to monitor over a longer time period so the changes in *integrated* and *end value* were more important than the absolute figure (LODE Diagnostics manual, 2000).

Spectroscopic Electrical Impedance Tomography (EIT)

Studies to develop and evaluate a new method of spectroscopic Electrical Impedance Tomography (EIT) have been taking place in Vrije Universy Brussel. It aims to reconstruct cross-sectional maps of site-specific electrical impedance spectra (EIS). This was suggested to improve upon existing electrical caries detection methods, both in terms of its improved cross-sectional sampling strategy, dispensing with the need to rely on visual surface indications to determine appropriate measurement sites, and its immunity with regard to the variability in electrical conductance between individual teeth. The tomographic representation will allow diagnostic interpretation to proceed depending on the relative changes in tissue impedance among different spatial locations, instead of being dependent on a single quantitative reading.

EIS, in a series of studies, in which EIS measurements of whole teeth were performed (Huysmans et al, 1996), it was suggested that this method may constitute an appreciable improvement over previous single frequency methods for the detection of small carious lesions. In EIT one seeks to reconstruct the internal conductivity profile of an object (Barber and Brown, 1983). To this end a current distribution was prescribed on its boundary, and the resulting voltage distribution was measured using a discrete array of surface electrodes. It was

regarded as a multi-electrode extension of the measurement configuration used in EIS.



Picture 1: ECM IV.

Picture 2: A low ECM *end value* reading (false positive) resulting from abraded points on the ECM probe tip touching the angle of the mouth and possible by the buccal mucosa touching the tooth.